

Development and clinical usefulness of a unique red dichromatic imaging technology in gastrointestinal endoscopy: A narrative review

Toshio Uraoka  and Makoto Igarashi

Ther Adv Gastroenterol

2022, Vol. 15: 1–11

DOI: 10.1177/
17562848221118302

© The Author(s), 2022.
Article reuse guidelines:
[sagepub.com/journals-
permissions](https://sagepub.com/journals-permissions)

Abstract: Image-enhanced endoscopy (IEE) allows real-time high-contrast imaging of a targeted lesion without any special equipment. Among various IEE technologies, narrow-band imaging, in which a light of shorter wavelength is used, emphasizes the surface and blood vessel patterns on the mucosal surface. This technology has been widely used in endoscopic diagnosis in the gastrointestinal tract. Red dichromatic imaging (RDI) was recently developed; it utilizes lights of longer wavelengths (520–550, 595–610, and 620–640 nm), which have weak light scattering characteristics in contrast to narrow-band imaging. RDI was designed to enhance the visibility of deep-lying blood vessels and areas of bleeding, and it has been installed in the latest Olympus endoscopy system, EVIS X1, as an advanced version of the optical-digital method that was originally developed. Improving the visibility of deep blood vessels allows more accurate evaluation of esophageal varices and the degree of inflammation in ulcerative colitis. Easier identification of a bleeding source makes hemostasis quicker and easier to accomplish during endoscopic resection procedures such as endoscopic submucosal dissection and peroral endoscopic myotomy as well as during treatment of gastrointestinal bleeding from a peptide ulcer or colon diverticulum. The authors herein review the technological development and principles, review the existing literature on RDI, and discuss the utility and effectiveness of this unique IEE technology in gastrointestinal endoscopy.

Keywords: endoscopic submucosal dissection, endoscopy, image-enhanced endoscopy, red dichromatic imaging

Received: 17 May 2022; revised manuscript accepted: 20 July 2022.

Introduction

The quality of endoscopic diagnosis has been remarkably improved by image-enhanced endoscopy (IEE) as represented by chromoendoscopy, narrow-band imaging (NBI), blue laser imaging, and the i-scan system (PENTAX Medical, Tokyo, Japan).¹ NBI is one of the most frequently used optical-digital methods in IEE, which utilizes narrow-band lights at the shorter wavelengths of blue light (390–445 nm) and green light (530–550 nm). These two narrow-band lights are strongly scattered in biological media by organelle-sized

particles such as mitochondria and cell nuclei at wavelengths that match the two absorption peaks of hemoglobin (Hb) in blood. In particular, short-wavelength light (390–445 nm) is useful at shallow depths of mucosal tissue because of its strong multiple light scattering effect. Therefore, NBI makes it possible to emphasize the capillary networks and surface structures on the mucosal surface, an understanding of which is useful for making an endoscopic diagnosis. NBI has been widely used in endoscopic detection and evaluation in the gastrointestinal tract.^{2,3}

Correspondence to:
Toshio Uraoka
Department of
Gastroenterology and
Hepatology, Gunma
University Graduate School
of Medicine, 3-39-22
Showa-machi, Maebashi
371-8514, Japan
uraoka@gunma-u.ac.jp;
toshi_uraoka@yahoo.co.jp
Makoto Igarashi Olympus
Corporation, Tokyo, Japan

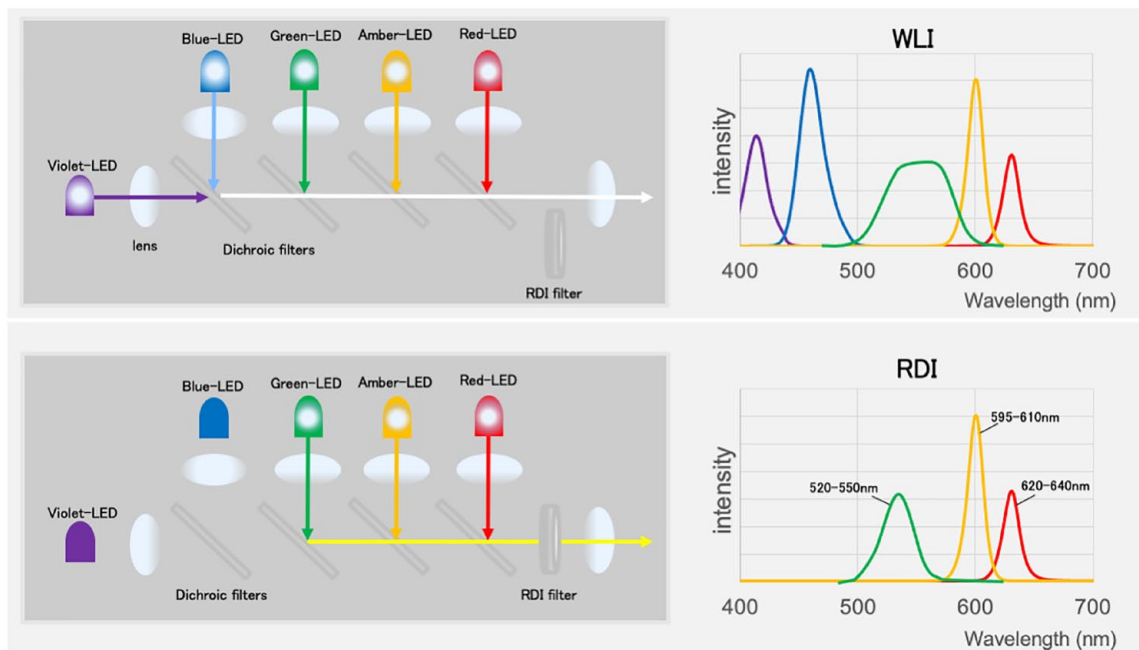


Figure 1. System configuration of EVIS X1 and wavelength characteristics of illuminations in WLI and RDI. RDI, red dichromatic imaging; WLI, white-light imaging.

Olympus recently developed red dichromatic imaging (RDI), which enables observation of deeper tissue regions by utilizing light of longer wavelengths; such light has weak light scattering characteristics, thus providing the opposite effect of NBI. The original purpose of RDI was to reduce the risk of bleeding during endoscopic treatment by improving the visibility of thick blood vessels in deeper tissues.

Although great efforts have been made in exploring the various clinical efficacies of RDI, no published reports have comprehensively covered both the technological and clinical aspects of RDI. The aim of this review is to describe the technological development and principles of the unique RDI technology, provide an overview of the existing literature, and discuss the utility and effectiveness of this technology in gastrointestinal endoscopy.

Development of the RDI system

The first feasibility study of RDI in humans was performed in 2011 under the term ‘dual red imaging’. Some institutions using regulatory-approved prototype systems based on a previous endoscopy system (EVIS LUCERA SPECTRUM or ELITE;

Olympus Co., Tokyo, Japan) subsequently evaluated dual red imaging in Japan. RDI has been installed in the latest endoscopy system, EVIS X1, as an advanced optical-digital method that was originally developed by Olympus. EVIS X1 was launched in Europe in April 2020 and in Japan in July 2020. RDI is mainly expected to be an imaging function that will contribute to safer and more efficient endoscopic treatments.

Wavelength characteristics of illumination light in the RDI system

Figure 1 shows the system configuration of the light source of EVIS X1. The light source unit consists mainly of five light-emitting diodes (LEDs) (violet, blue, green, amber, and red LEDs), dichroic filters, and an optical filter (RDI filter). All five LEDs emit light during a white-light imaging (WLI) observation. Because RDI uses three narrow-band lights of longer wavelengths (520–550, 595–610, and 620–640 nm), only three LEDs (green, 520–550 nm; amber, 595–610 nm; and red, 620–640 nm) emit light during RDI observation. After the three LED lights are combined by dichroic filters, the spectrum of the combined light can be narrowed by the RDI filter inserted onto the optical axis.


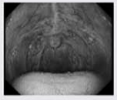
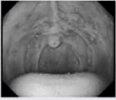
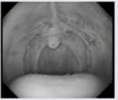
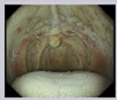
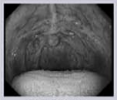
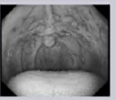
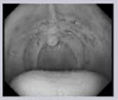

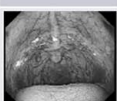
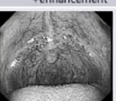
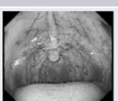
RDI mode	Color image	Monochromatic image			Characteristics	Expected clinical impacts
		Blue channel	Green channel	Red channel		
mode 1		 520-550nm	 595-610nm	 620-640nm	Enhance bleeding areas and indigo carmine	<ul style="list-style-type: none"> Quick and effective hemostasis Identify demarcation line of muscle layer in ESD and POEM
mode 2		 520-550nm	 595-610nm +enhancement	 620-640nm	Enhance deep blood vessels more than mode 1	<ul style="list-style-type: none"> Identify deep blood vessels for initial local injection during ESD or POEM Predict the depth of esophageal varices
mode 3		 520-550nm	 520-550nm +enhancement	 620-640nm +enhancement	Enhance both superficial and deep vessels	<ul style="list-style-type: none"> Evaluate the severity of ulcerative colitis Observe mucosal tissue through residual stool during colonoscopy

Figure 2. Color allocations and three imaging modes of RDI. RDI, red dichromatic imaging.

Color allocations and subimaging modes of RDI

RDI has three observational modes depending on the purpose of its use. As shown in Figure 2, RDI mode 1, which enhances the visibility of thick blood vessels in deep tissues, allocates each monochromatic image taken by the narrow-band lights of 520–550, 595–610, and 620–640 nm to blue, green, and red channels in ascending order of wavelength. Next, in RDI mode 2, the allocation of each monochromatic image to an RGB channel is the same as in mode 1, but the visibility of thick blood vessels is more strongly emphasized in mode 2 than in mode 1 by allocating a blood vessel-enhanced image obtained at 595–610 nm to the green channel, utilizing an original image of 620–640 nm. RDI mode 3 allocates a monochromatic image of 520–550 nm to the blue channel and green channel and a monochromatic image of 595–610 nm with the same blood vessel-enhancement processing as in mode 2 to the red channel. The features of mode 3 emphasize both thick blood vessels in deep tissues and relatively thin blood vessels in the mucosa.

RDI mode 1, 2, or 3 can also be instantly switched from WLI to RDI and vice versa by pressing a single button of top on the endoscope.

Principles and clinical impact of RDI

Through proper use of each observational mode for specific medical applications, RDI is expected

to be beneficial in many tasks ranging from diagnosis to treatment in gastrointestinal endoscopy. We describe the principles and various clinical impacts of RDI below.

Enhancement of thick blood vessels in deep tissue

Principles. As Figure 3 shows, Hb strongly absorbs narrow-band amber light (595–610 nm) but minimally absorbs narrow-band red light (620–640 nm). In addition, because the two narrow-band lights have weak light scattering characteristics in biological media, they can penetrate more deeply into the tissue. If a deep blood vessel exists, narrow-band light of 595–610 nm is absorbed by Hb in blood, and the reflected light intensity is thus attenuated depending on the concentration of Hb and the volume of blood in the deep blood vessel. In contrast, the intensity of reflected light with a wavelength of 620–640 nm is high because of its low absorption by Hb. When no thick blood vessels exist in the deep part of tissue, both of the reflected lights can be detected at higher intensity because of the absence of light absorption by Hb. Therefore, RDI can provide enhanced visualization of a thick blood vessel based on the degree of attenuation of the intensity of 595–610 nm reflected light versus that of 620–640 nm reflected light. One experiment confirmed that thick blood vessels, which are difficult to identify by WLI and NBI, located at a depth of ≥ 1.2 mm can be visualized by RDI (Figure 4).

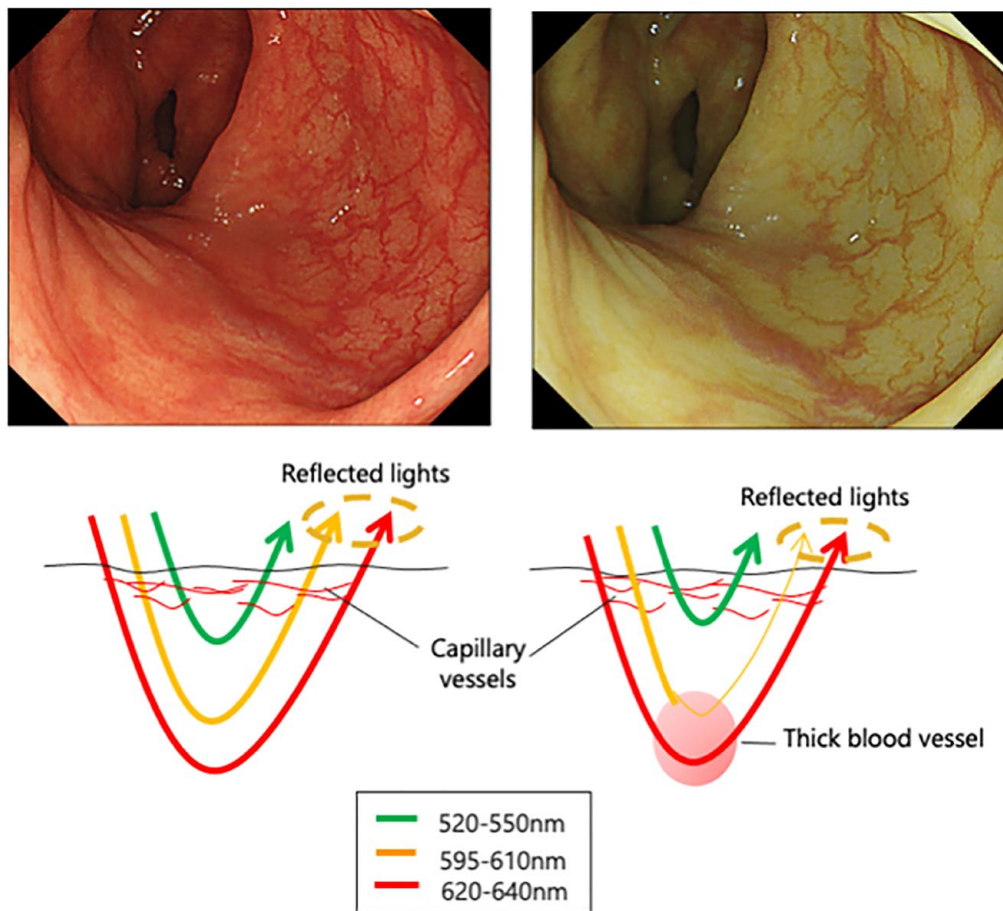


Figure 3. Principle by which RDI improves the visibility of a thick blood vessel in deep tissue and the experimental results confirming the principle. RDI, red dichromatic imaging.

Clinical impact. As the first step in evaluating the visibility of a vessel by RDI, a feasibility study was conducted to compare the visibility of blood vessels using still endoscopic images of human healthy mucosa and submucosa.⁴ The visibility scores were significantly better in a prototype of RDI than in WLI for all observers in this study. The results of this study led to easy identification of vessels and helped to avoid vessels when performing submucosal injections during endoscopic resection techniques such as endoscopic mucosal resection and endoscopic submucosal dissection (ESD). Actually, in rectal ESD, we have demonstrated the usefulness of EVIS X1 system-based RDI in decreasing the bleeding during the submucosal injection phase.

Visibility of esophageal varices. The use of RDI is expected to enhance the visibility of esophageal varices (EVs). Furuichi *et al.*⁵ evaluated the

ability of a prototype of RDI to enhance the visibility of EVs using endoscopic ultrasonography. They found that RDI enables prediction of the depth of EVs based on their color and thickness and that the visibility of EVs positioned at a shallow depth from the epithelium was more strongly enhanced by RDI. Further studies are needed to determine whether RDI can replace endoscopic ultrasonography for visualization of EVs. The authors subsequently reported that RDI rather than WLI can decrease the recurrence rate of EVs because RDI facilitates accurate intravariceal injections during endoscopic injection sclerotherapy of EVs.⁶ Their data showed that RDI improved the intrajection success rate during endoscopic injection sclerotherapy depending on the prediction of the depth of EVs by the degree of change in their visibility. They also suggested that the current RDI technology based on the EVIS X1 system can improve the

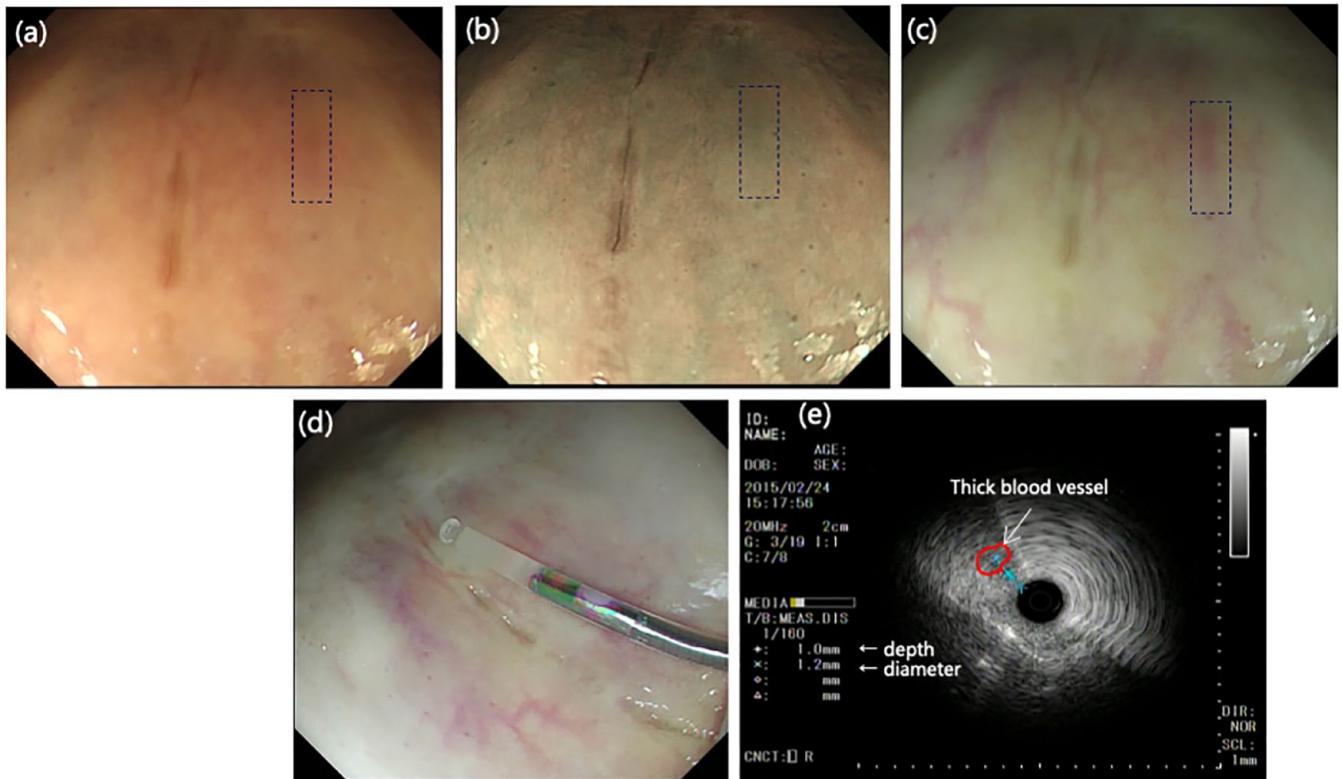


Figure 4. Endoscopic images of human oral tissue captured by (a) WLI, (b) NBI, and (c) RDI. A thick blood vessel is present in a dotted square frame of each image. (d) Ultrasonography measurements for the thick blood vessel that was enhanced only by RDI. (e) Ultrasound image of the thick blood vessel captured by a probe system with a frequency of 20 MHz (EU-ME1, UM-BS20-26R; Olympus Co., Tokyo, Japan). RDI, red dichromatic imaging; WLI, white-light imaging; NBI, narrow-band imaging.

visibility of EVs.⁷ RDI mode 2 is recommended for the observation of EVs.

Evaluation of disease activity in patients with ulcerative colitis. RDI can identify blood vessels in deeper tissues through the mucosa in patients with mild to moderate ulcerative colitis. Naganuma *et al.*⁸ established RDI scores based on the visibility of blood vessels. The RDI score was closely correlated with both the endoscopic and histological grades. They demonstrated that RDI could be used to separate patients with the same Mayo endoscopic score⁹ into groups with RDI scores of 2 or 3–4. RDI mode 3 is recommended for the observation of such vessels in patients with ulcerative colitis. A validation study using RDI based on the EVIS X1 system is needed to confirm the usefulness of RDI.

Enhancement of bleeding point with different colors

Principles. Narrow-band light of 595–610 nm is more strongly absorbed than light of 620–640 nm

when these lights hit a bleeding point at which the Hb concentration is very high (or the blood volume is large). The intensity of reflected light with a wavelength of 595–610 nm is attenuated depending on the concentration and volume of blood at the bleeding point. Because both lights are less strongly absorbed by Hb in the peripheral area of a bleeding point, where the blood concentration is low (or the blood volume decreases as the blood layer becomes thinner), these reflected lights are detected with equally high intensity. Therefore, a bleeding point and its peripheral area are displayed in different colors based on the degree of attenuation of the intensity of 595–610 nm reflected light versus that of 620–640 nm reflected light. The special image processor installed in RDI properly adjusts a bleeding point to be represented in orange and its peripheral area in yellow.

Preliminary experiments using a bleeding tissue model revealed two main findings as shown in Figure 5. First, the color contrast of the bleeding

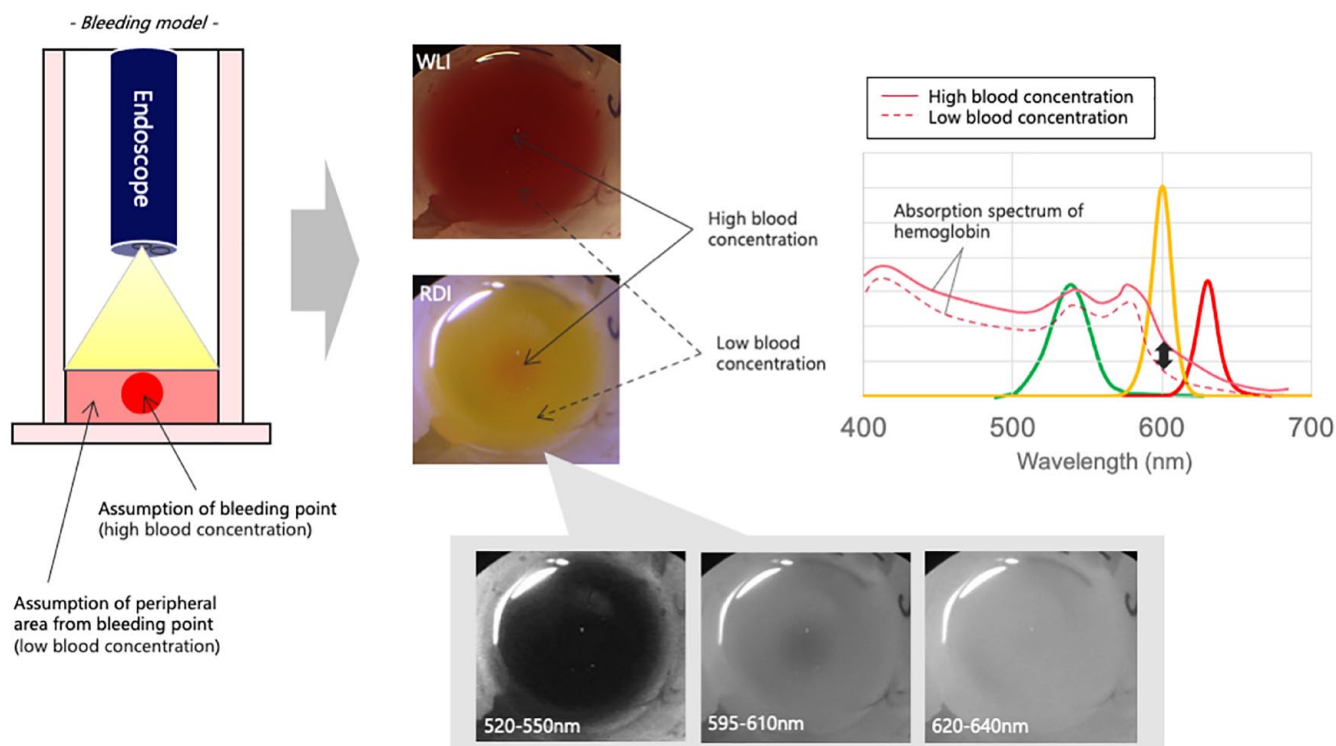


Figure 5. Principle by which RDI improves the visibility of a bleeding source and the experimental results confirming the principle. RDI, red dichromatic imaging.

points was significantly improved by RDI compared with WLI. Second, RDI assigns different colors (orange and yellow) to each region in which the blood concentrations differ.

Enhancement of bleeding point with 'see-through effect'

Principles. RDI has been clinically confirmed to increase the transparency of bleeding areas with a low blood concentration (or low blood volume). Because absorption of light of longer wavelengths by Hb becomes extremely weak in the peripheral area of a bleeding point, where the blood concentration is low (or the blood volume is small), lights of 595–610 nm and 620–640 nm can penetrate biological tissues under a blood layer and are just as likely to be detected as are strongly reflected lights. This is considered to support the hypothesis that RDI enhances the transparency of areas with a low blood concentration, whereas the visibility is low at bleeding points and thick blood vessels where the blood concentration is very high (or the blood volume is large).

To confirm this hypothesis, the visibility of a blood vessel phantom under a blood layer was experimentally evaluated as shown in Figure 6. This figure shows that RDI significantly improved the visibility of the blood vessel phantom under a blood layer when compared with other modalities. This result was obtained because RDI utilizes more illumination lights than WLI and NBI in the wavelength range that is less strongly absorbed by Hb. Furthermore, RDI increases the transparency of bile juice as well as that of blood. In our preliminary animal study, RDI in mode 3 allowed observation of the mucosal tissue and blood vessels under bile juice because the illumination lights that RDI employs were weakly absorbed by bilirubin in bile juice. RDI optically enhances the transparency of residual stool by the same principle.

Clinical impact

Hemostasis of intraoperative bleeding during endoscopic procedures. ESD can achieve *en bloc* resection even of large early-stage gastrointestinal tumors with severe scarring because this procedure enables direct identification of the cutting

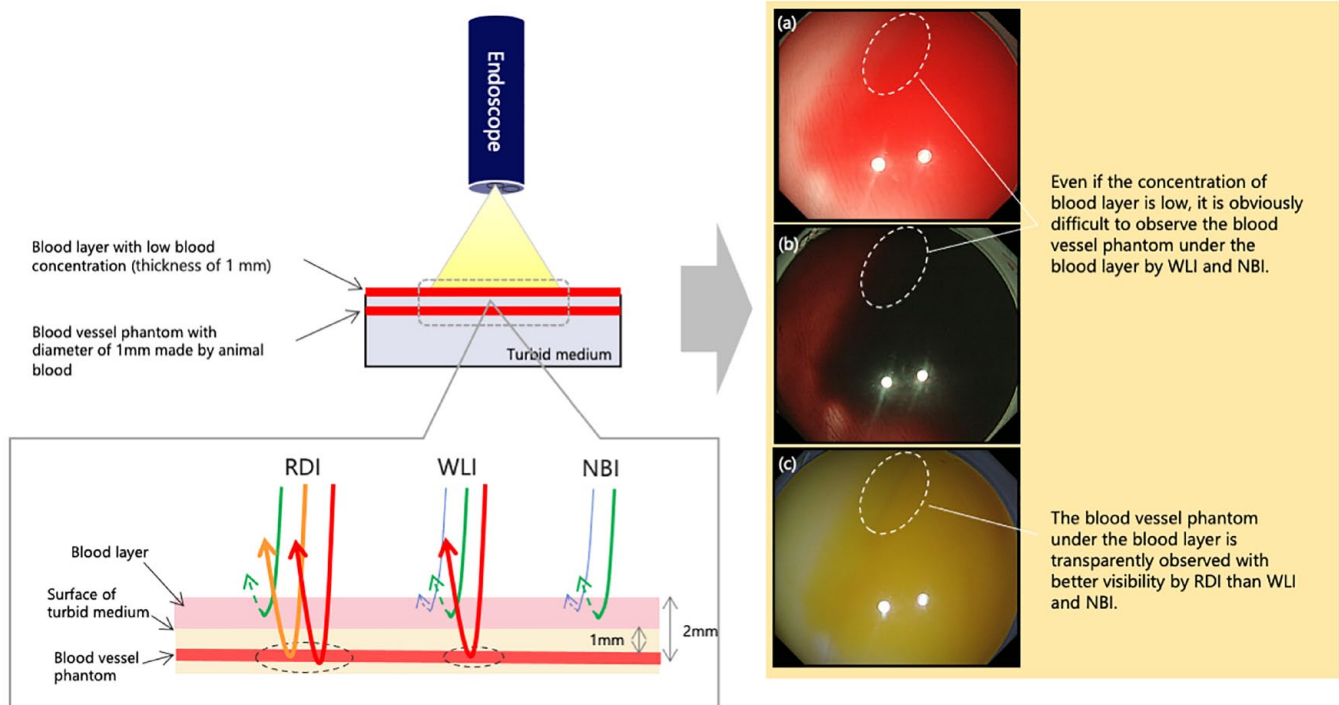


Figure 6. Experimental results demonstrating the effect of seeing through blood for (a) WLI, (b) NBI, and (c) RDI. RDI, red dichromatic imaging; WLI, white-light imaging; NBI, narrow-band imaging.

line using an ESD knife during the submucosal dissection. Intraoperative bleeding is unavoidable during the mucosal incision and submucosal dissection, and appropriate endoscopic hemostasis using coagulation forceps or the tip of an ESD knife is required to manage bleeding from exposed vessels at the ulcer base or submucosal layer. However, it is sometimes difficult to maintain clear visibility and rapidly identify the bleeding points.

RDI with mode 1 can facilitate endoscopic hemostasis during ESD by displaying the bleeding points in a yellow or orange color that can be more easily seen by the operator. The color allows the operator to clearly distinguish bleeding points from veins as well as pressure-related bleeding, such as bleeding from arteries. Several investigators have reported the usefulness of a prototype of RDI during gastric and colorectal ESD.^{10–13} Yorita *et al.*¹⁰ reported that the visibility of bleeding points was better in 55% of cases when using RDI than when using WLI. In addition, the number of coagulations needed for complete hemostasis was lower in the RDI group than in the WLI group. A multicenter randomized controlled trial

was conducted to clarify the management of intraoperative bleeding during ESD using RDI.¹¹ RDI also helped to accurately identify the dissection line during gastric ESD by the see-through effect even in the difficult situation involving the presence of a submucosal layer with a hematoma.¹² Furthermore, RDI was reportedly useful in maintaining clear visibility during ESD, even in submucosal tissue with a large amount of fat tissue.¹³

Based on the abovementioned benefits of RDI, we suggest performing ESD using full-time RDI.¹⁴ This procedure is expected to shorten the operation time while maintaining a safer situation.

Kv *et al.*¹⁵ also reported that the use of RDI leads to early identification of bleeding points and quicker hemostasis during peroral endoscopic myotomy (POEM) and ESD in patients with achalasia. Prospective studies are needed to fully assess the usefulness of RDI in the endoscopic identification of deep blood vessels and bleeding points during submucosal endoscopy procedures such as ESD and POEM.

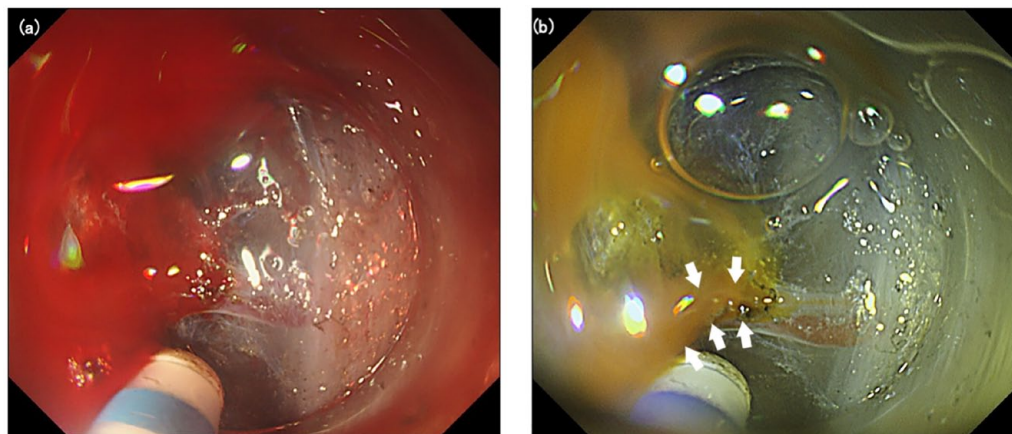


Figure 7. The color provides clearer identification of bleeding points by (b) RDI than by (a) WLI. RDI, red dichromatic imaging; WLI, white-light imaging.

Hemostasis of acute gastrointestinal bleeding. Patients with acute gastrointestinal bleeding from peptic ulcers or colonic diverticula undergo urgent endoscopy for endoscopic hemostasis using various techniques. Hemostatic forceps or endo-clips are useful for managing bleeding from exposed vessels at the base of peptic ulcers. However, the identification of such vessels and bleeding sources is sometimes difficult because of the high bleeding activity, massive blood volume, and poor visibility in the pool of blood under WLI. Kubosawa *et al.*¹⁶ and Tanaka *et al.*¹⁷ reported on the usefulness of RDI in endoscopic hemostasis of gastric and duodenal bleeding, respectively. In addition, RDI has made it easy to identify bleeding diverticula in the colon, as described by Saino *et al.*¹⁸ All reports mentioned the enhancement of the evidence for recent bleeding points with different colors and see-through effects by RDI. Because all reports on the usefulness of RDI to date have been case presentations, a prospective study on the efficacy of this technique is warranted.

Enhancement of demarcation line between submucosal layer and muscularis layer

Principles. One report discussed the principles by which RDI emphasizes the submucosal layer after local injection of indigo carmine during ESD.¹⁹ According to the light absorption characteristics of indigo carmine, shown as the dotted line in Figure 8, parts of the broadband green light and the broadband red light used in WLI are strongly absorbed by indigo carmine. This is why WLI displays the submucosal layer containing indigo carmine in turquoise blue. In contrast,

lights of 595–610 and 620–640 nm are more strongly absorbed by indigo carmine than is light of 520–550 nm. Therefore, the submucosal layer containing indigo carmine is displayed in deep blue in RDI mode 1 or 2. Furthermore, in principle, RDI displays the color tone of the muscular layer adjacent to the submucosal layer in pale yellow. Importantly, a submucosal layer in deep blue and a muscular layer in light yellow have an almost complementary color relationship according to color theory. Because complementary color pairs generally enhance each other's intensity, the visibility of the demarcation line of the muscularis layer should be drastically better in RDI than in WLI. In preliminary experiments using resected stomach tissue of an animal, the color contrast between the submucosal and muscular layers was indeed more strongly enhanced by RDI than WLI as the concentration of indigo carmine increased (Figures 7 and 8).

Clinical impact

Estimation of dissection line in ESD and POEM. Adding indigo carmine dye to the submucosal injection solution enhances the visibility of the submucosal layer before mucosal or submucosal cutting in ESD and POEM. In the clinical setting, RDI is useful for enhancement of the submucosal layer. Ninomiya *et al.*¹⁹ reported that dual red imaging improves the visibility of vessels, especially that of arteries, because they appear orange in the submucosa layer with indigo carmine. In our experience, a higher concentration of indigo carmine improves identification of the submucosal layer and results in safer submu-

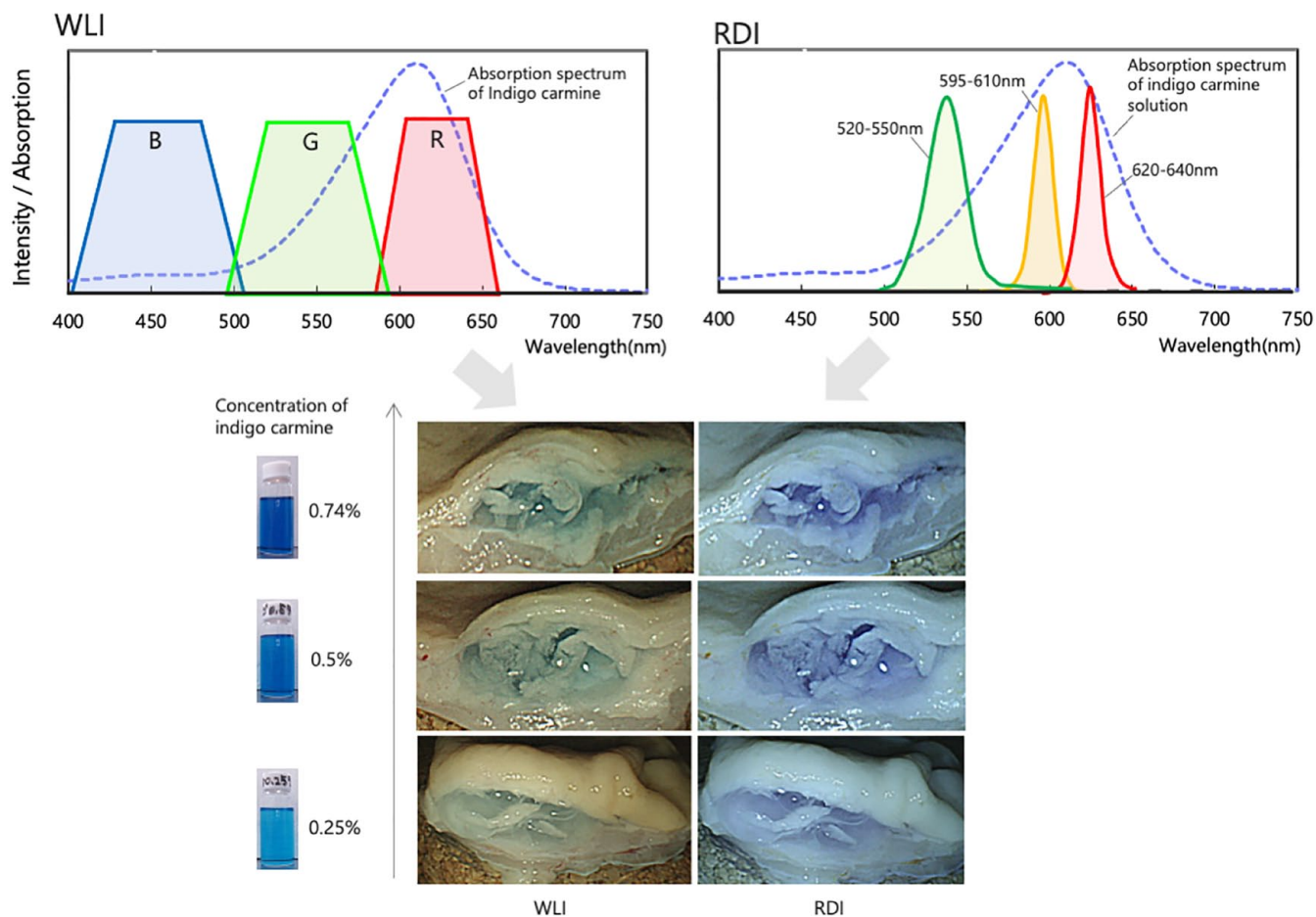


Figure 8. Principle by which RDI improves an endoscopic image after indigo carmine injection into the submucosal layer and the experimental results confirming the principle. The endoscopic images were obtained from the resected stomach of a pig. RDI, red dichromatic imaging.

cosal dissection. We suggest that this blue color enhancement is one of the benefits of full-time RDI in ESD or POEM.

Conclusions

RDI has been developed as a unique advanced optical-digital image technology that contributes to obtaining quick and effective hemostasis and accurately identifying deep vessels in the gastrointestinal tract, thus reducing the risk of bleeding and facilitating evaluation of the therapeutic efficacy. Because RDI has been installed in EVIS X1, this unique endoscopic imaging technology is expected to become widely used around the world. It is important for users to understand the technological principles and appropriate settings of RDI before using it. We anticipate that further

studies will prove RDI to be a useful imaging technology in gastrointestinal endoscopy.

Declarations

Ethics approval and consent to participate

Written informed consent was obtained from the patient for publication of this review paper and accompanying images.

Consent for publication

We have obtained appropriate consent for publication.

Author contribution(s)

Toshio Uraoka: Conceptualization; resources; writing – original draft.

Makoto Igarashi: Resources; writing – review and editing.

Acknowledgements

We are grateful to Yuichiro Hirai for his assistance in the editing of this manuscript. We also thank Angela Morben, DVM, ELS, from Edanz, for editing a draft of this manuscript. Olympus Corporation was only involved in providing technical materials and data in this paper.

Funding

The authors received no financial support for the research, authorship, and/or publication of this article.

Competing interests

Dr Toshio Uraoka has received lecture fees from Olympus Co. Dr Makoto Igarashi works for Olympus Co. as an engineer and a strategist.

Availability of data and materials

Not applicable.

ORCID iD

Toshio Uraoka  <https://orcid.org/0000-0002-4425-4331>

References

1. Gono K, Obi T, Yamaguchi M, *et al.* Appearance of enhanced tissue features in narrow-band endoscopic imaging. *J Biomed Opt* 2004; 9: 568–577.
2. Sano Y, Tanaka S, Kudo S-E, *et al.* Narrow-band imaging (NBI) magnifying endoscopic classification of colorectal tumors proposed by the Japan NBI Expert Team. *Dig Endosc* 2016; 28: 526–533.
3. Muto M, Minashi K, Yano T, *et al.* Early detection of superficial squamous cell carcinoma in the head and neck region and esophagus by narrow band imaging: a multicenter randomized controlled trial. *J Clin Oncol* 2010; 28: 1566–1572.
4. Yahagi N, Fujimoto A, Horii J, *et al.* Dual red imaging: a novel endoscopic imaging technology visualizing thick blood vessels in the gastrointestinal wall. *Endosc Int Open* 2019; 7: E1632–E1635.
5. Furuichi Y, Gotoda T, Moriyasu F, *et al.* Dual red imaging (novel advanced endoscopy) can increase visibility and can predict the depth in diagnosing esophageal varices. *J Gastroenterol* 2017; 52: 568–576.
6. Furuichi Y, Gotoda T, Kasai Y, *et al.* Role of dual red imaging to guide intravascular sclerotherapy injection of esophageal varices (with videos). *Gastrointest Endosc* 2018; 87: 360–369.
7. Furuichi Y, Abe M, Kasai Y, *et al.* Secure intravascular sclerotherapy with red dichromatic imaging decreases the recurrence rate of esophageal varices: a propensity score matching analysis. *J Hepatobiliary Pancreat Sci* 2021; 28: 431–442.
8. Naganuma M, Yahagi N, Bessho R, *et al.* Evaluation of the severity of ulcerative colitis using endoscopic dual red imaging targeting deep vessels. *Endosc Int Open* 2017; 5: E76–E82.
9. Schroeder KW, Tremaine WJ and Ilstrup DM. Coated oral 5-aminosalicylic acid therapy for mildly to moderately active ulcerative colitis. A randomized study. *N Engl J Med* 1987; 317: 1625–1629.
10. Yorita N, Oka S, Tanaka S, *et al.* Clinical usefulness of dual red imaging in gastric endoscopic submucosal dissection: a pilot study. *Clin Endosc* 2020; 53: 54–59.
11. Fujimoto A, Saito Y, Abe S, *et al.* Haemostasis treatment using dual red imaging during endoscopic submucosal dissection: a multicentre, open-label, randomised controlled trial. *BMJ Open Gastroenterol* 2019; 6: e000275.
12. Miyamoto S, Ohya TR, Nishi K, *et al.* Effectiveness of red dichromatic imaging for dissection of the submucosal layer when hematoma is encountered. *Endoscopy* 2021; 53: E413–E414.
13. Tanaka H, Oka S, Tanaka S, *et al.* Dual red imaging maintains clear visibility during colorectal endoscopic submucosal dissection. *Dig Dis Sci* 2019; 64: 224–231.
14. Kita A, Tanaka H, Ramberan H, *et al.* Endoscopic submucosal dissection of early-stage rectal cancer using full-time red dichromatic imaging to minimize and avoid significant bleeding. *VideoGIE* 2021; 6: 193–194.
15. Kv A, Ramchandani M, Inavolu P, *et al.* Red dichromatic imaging in peroral endoscopic myotomy: a novel image-enhancing technique. *VideoGIE* 2021; 6: 203–206.
16. Kubosawa Y, Mori H and Fujimoto A. Utility of dual red imaging for endoscopic hemostasis of gastric ulcer bleeding. *Dig Dis* 2020; 38: 352–354.

17. Tanaka H, Oka S and Tanaka S. Endoscopic hemostasis for spurting duodenal bleeding using dual red imaging. *Dig Endosc* 2017; 29: 816–817.
18. Saino M, Aoyama T, Fukumoto A, *et al.* Tracking the target in colonic diverticular bleeding using red dichromatic imaging. *Endoscopy* 2021; 53: E425–E426.
19. Ninomiya Y, Oka S, Tanaka S, *et al.* Clinical impact of dual red imaging in colorectal endoscopic submucosal dissection: a pilot study. *Therap Adv Gastroenterol* 2016; 9: 679–683.

Visit SAGE journals online
[journals.sagepub.com/
home/tag](https://journals.sagepub.com/home/tag)

 SAGE journals