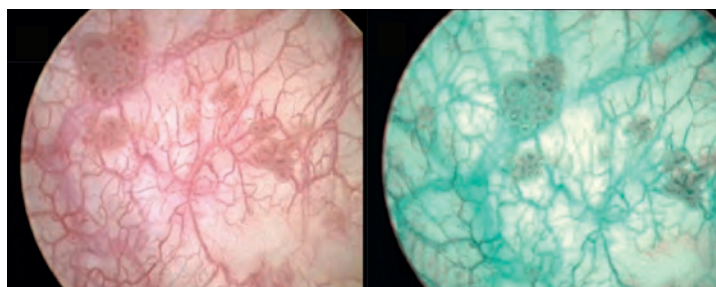


## NARROW BAND IMAGING® CYSTOSCOPY IMPROVES THE DETECTION OF NON-MUSCLE INVASIVE BLADDER CANCER

Evelyne C.C. Cauberg, Sarah Kloen, Mike Visser, Jean J.M.C.H. de la Rosette, Marko Babjuk, Viktor Soukup, Michael Pesl, Jaroslava Duskova, Theo M. de Reijke  
*Department of Urology, Medical Center, Amsterdam, The Netherlands*

### OBJECTIVE

To determine whether Narrow Band Imaging (NBI®) improves detection of non-muscle invasive bladder cancer (NMIBC) over white light imaging (WLI) cystoscopy.



WLI image of multiple pTaG1 tumours (Left); Enhanced contrast of same tumours with NBI (Right)

### METHODS

The researchers conducted a prospective, within-patient comparison on 103 consecutive procedures on 95 patients scheduled for (re-)transurethral resection of a bladder tumor or bladder biopsies in the Academic Medical Center, Amsterdam (September 2007-July 2009) and in the General Faculty Hospital, Prague (January-July 2009). WLI and NBI cystoscopy were subsequently performed by different surgeons who independently indicated all tumors and suspect areas on a bladder diagram. The lesions identified were resected/biopsied and sent for histopathological examination. The number of patients with additional tumors detected by WLI and NBI were calculated; the mean number of urothelial carcinomas (UCs) per patient, detection rates and false-positive rates of both techniques were compared.

### EQUIPMENT USED

- 24 French rigid endoscope (OESPro, Olympus Medical Systems), connected to an Olympus Evis Exera II Xenon light source

### RESULTS

A total of 78 patients had a confirmed UC; there were 226 tumors in total. In 28 (35.9%) of these patients, a total of 39 additional tumors (17.3%) (26pTa, 6pT1, 1pT2, 6pTis) were detected by NBI, whereas 4 additional tumors (1.8%) (1pTa, 1pT1, 2pTis) within 3 patients (2.9%) were detected by WLI. The mean (SD, range) number of UCs per patient identified by NBI was 2.1 (2.6, 0-15), versus 1.7 (2.3, 0-15) by WLI ( $p < 0.001$ ). The detection rate of NBI was 94.7% versus 79.2% for WLI ( $p < 0.001$ ). The false-positive rate of NBI and WLI was 31.6% and 24.5%, respectively ( $p < 0.001$ ).

## CONCLUSIONS

This preliminary study has demonstrated that NBI cystoscopy significantly improves detection of primary and recurrent NMIBC over WLI, particularly for Ta and G3 lesions. The false-positive rate of NBI is somewhat higher compared with WLI, even higher for recurrent tumors and after intravesical instillations, but still seems acceptable. Whether NBI-assisted TUR also results in decreased early “recurrence” rates and longer disease-free interval still has to be evaluated in future trials.

Note: This summary is for informational purposes only. Publication abstract and access to full article can be found at:

<http://www.ncbi.nlm.nih.gov/pubmed/20223505>

Ref: doi: 10.1016/j.urology.2009.11.075